

This is an official
CDC HEALTH UPDATE

Distributed via the CDC Health Alert Network
March 4, 2013, 16:30 ET (4:30 PM ET)
CDCHAN-00342

**Notice to Clinicians: Continued Vigilance Urged for
Fungal Infections among Patients Who Received
Contaminated Steroid Injections**

Summary

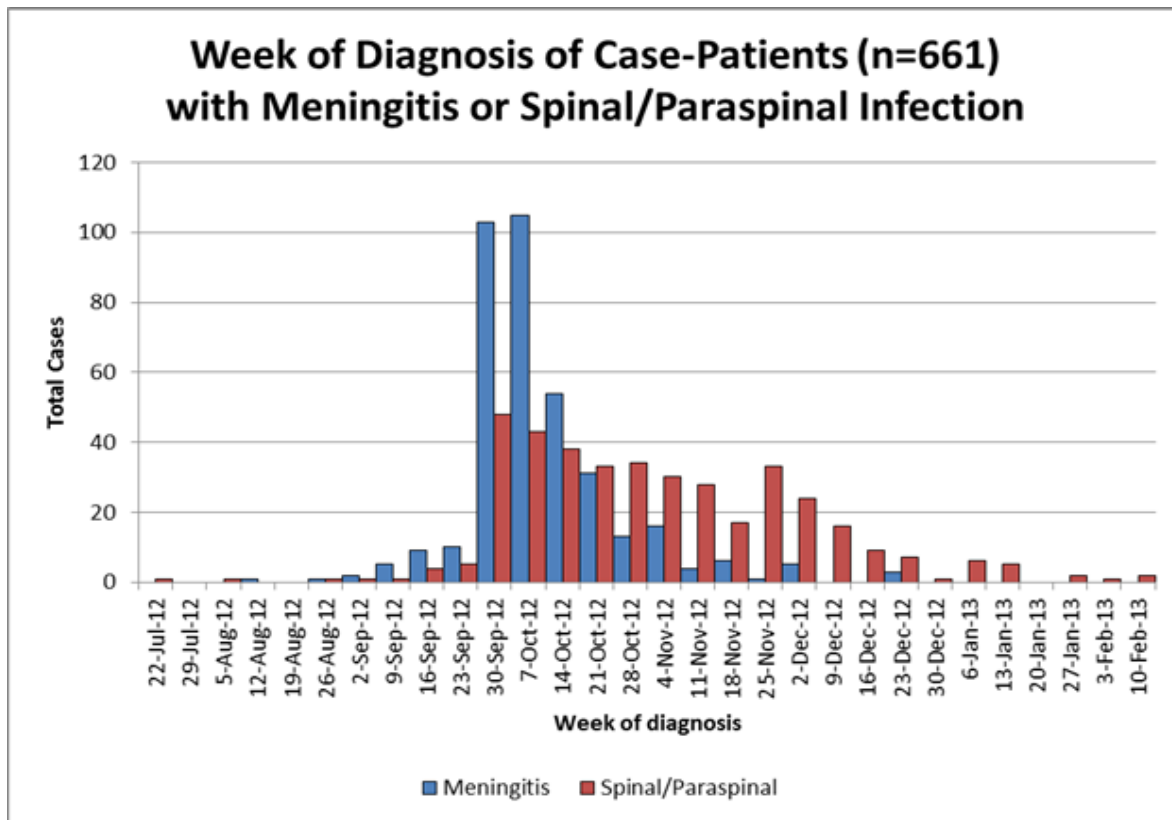
CDC continues to receive new reports of fungal infection among patients who were given injections of contaminated methylprednisolone acetate (MPA¹) from the New England Compounding Center (NECC) in Framingham, Mass. Most of these recent cases have been localized spinal or paraspinal infections (e.g., epidural abscesses) in patients, although new cases of meningitis or arachnoiditis also have been reported. Because many of these new cases are among patients with minimal symptoms, CDC is re-emphasizing the recommendation for clinicians to remain vigilant for fungal infections, especially in patients with mild or even baseline symptoms, and consider evaluation with magnetic resonance imaging (MRI) if clinically warranted. This Health Alert Network (HAN) notice provides the following:

- Information about the current status of the outbreak;
- Recommendations for clinical management and follow-up of exposed patients;
- Information about new revisions to web-based interim clinical guidance (http://www.cdc.gov/hai/outbreaks/clinicians/guidance_cns.html); and
- Notice of an upcoming CDC conference call to provide clinicians with additional diagnostic and treatment information.

Status of Fungal Disease Outbreak

As of March 4, 2013, a total of 720 cases, which includes 48 deaths, have been reported in 20 states. Current information about the outbreak, including case counts and distribution by state, and clinician and patient guidance, is available online at <http://www.cdc.gov/hai/outbreaks/meningitis.html>.

Fungal meningitis, often with a mild clinical presentation, was the predominant clinical syndrome reported among case-patients during the first several weeks of the outbreak (figure). Over the past several months, there has been a marked decrease in reports of fungal meningitis, but CDC continues to receive reports of localized spinal and paraspinal infections, which include epidural abscess, phlegmon, arachnoiditis, and discitis. Additionally, some of these newly identified case-patients had initially tested negative for signs of a fungal infection (either by lumbar puncture or MRI) and have subsequently developed fungal infection, indicating a prolonged incubation period.



After the recall of NECC steroid medications on September 26, state and local health departments identified almost 14,000 people in 23 states who were potentially exposed to the implicated MPA; of these, an estimated 11,000 individuals received spinal or paraspinal injections. Through active notification by clinics with assistance from states and CDC in early October, nearly all of these exposed persons were contacted at least once and informed of their risk for fungal infection as a result of receiving injections with contaminated medication.

Despite this and subsequent patient outreach efforts, CDC and public health partners remain concerned about the potential for some exposed patients to have localized fungal infections that have gone unrecognized. These infections may be unrecognized because some patients have not continued to receive close clinical follow-up or because they have not recognized symptoms suggestive of a localized infection, which may be difficult to distinguish from their baseline chronic pain.

As described in CDC's HAN update on December 20 (<http://emergency.cdc.gov/HAN/han00338.asp>), MRI testing was done on 128 patients in Michigan, Tennessee, and North Carolina who had no previous evidence of infection and had new or worsening symptoms at or near the site of their spinal or paraspinal injection. Of these, 67 (52%) had findings suggestive of localized infection. In addition, of 109 different patients reporting persistent but baseline symptoms at or near the site of their spinal or paraspinal injection, 15 (14%) also had abnormal MRI findings suggestive of infection, and 27 (25%) had non-specific enhancement of soft tissue or other paraspinal structures. The clinical significance of these findings is unclear; however, there is a theoretical risk that failure to diagnose these infections in a timely fashion could result in poor outcomes for patients (e.g., neurologic compromise, osteomyelitis, or progression to meningitis).

Patient and Clinician Recommendations

Early in the outbreak, CDC advised clinicians to closely monitor and evaluate patients who received injections of implicated MPA. Additional guidance was provided in HAN updates issued on November 20 (<http://emergency.cdc.gov/HAN/han00335.asp>) and December 20 (<http://emergency.cdc.gov/HAN/han00338.asp>). Because of the possibility that some patients may have unrecognized, localized fungal infections, CDC is re-emphasizing the following recommendations for patients who received a spinal or paraspinal injection with implicated MPA:

Patients

Patients who received an injection in or near their spine from one of the three implicated lots of MPA¹ and who have any symptoms at or near the site of their injection should seek evaluation by their medical provider for the possibility of a localized infection, such as an epidural abscess. This includes patients who initially received steroid injections for pain and continue to have persistent baseline pain.

Clinicians

As a part of continued monitoring of patients who received an injection with implicated MPA, clinicians should consider re-evaluating patients who received a spinal or paraspinal injection with implicated MPA for signs and symptoms suggestive of infection, including any symptoms at or near the site of their injection. Because of the prolonged incubation period for these infections, this guidance pertains both to patients who have not been previously evaluated and to those who have already had a prior negative evaluation (e.g., normal cerebrospinal fluid profile, normal findings on MRI) but continue to have complaints:

- In patients with new or worsening symptoms at or near the site of their injection, clinicians should obtain an MRI with contrast of the symptomatic area(s).
- In patients with persistent but baseline symptoms, clinicians should consider obtaining an MRI with contrast of the symptomatic area(s) because the presentation of spinal or paraspinal infections can be subtle, and may be difficult to distinguish from a patient's baseline chronic pain.
- In some cases, radiologic evidence of abscess or phlegmon has become apparent on repeat MRI studies performed subsequent to an initially normal imaging procedure. Clinicians should therefore have a low threshold for repeat MRI studies in patients who continue to have symptoms localizing to the site of injection, even after a normal study. However, the optimal duration between MRI studies is unknown.
- Clinicians should also consider reviewing MRI results with a neuroradiologist because of potential difficulties in interpreting imaging results for these patients.

Revised Clinical Guidance and Clinician Information Call

In response to input from expert consultants on fungal disease and physicians who have been treating patients affected by this outbreak, CDC has revised its Interim Treatment and Diagnostic Guidance for Central Nervous System and Parameningeal Infections Associated with Injection of Contaminated Steroid Products (http://www.cdc.gov/hai/outbreaks/clinicians/guidance_cns.html). The revisions include addition of new information on several topics, including:

- Surgical management of parameningeal disease
- Duration of antifungal treatment
- Monitoring clinical status after cessation of antifungal treatment
- Information on non-first-line medications (e.g., posaconazole or itraconazole)

A conference call for clinicians interested in obtaining additional information about the management and treatment of patients with fungal illness associated with this outbreak has been scheduled for March 13 at 5:00 p.m. The presenter will be Tom Chiller, M.D., medical officer, CDC. Registration and call-in information and other details about the conference call will be available on CDC's website <http://www.cdc.gov/hai/outbreaks/clinicians/index.html>.

¹NECC lots of methylprednisolone acetate (PF) 80mg/ml:

Methylprednisolone Acetate (PF) 80 mg/ml Injection, Lot #05212012@68, BUD 11/17/2012

Methylprednisolone Acetate (PF) 80 mg/ml Injection, Lot #06292012@26, BUD 12/26/2012

Methylprednisolone Acetate (PF) 80 mg/ml Injection, Lot #08102012@51, BUD 2/6/2013

The Centers for Disease Control and Prevention (CDC) protects people's health and safety by preventing and controlling diseases and injuries; enhances health decisions by providing credible information on critical health issues; and promotes healthy living through strong partnerships with local, national, and international organizations.

Categories of Health Alert Network messages:

Health Alert Requires immediate action or attention; highest level of importance

Health Advisory May not require immediate action; provides important information for a specific incident or situation

Health Update Unlikely to require immediate action; provides updated information regarding an incident or situation

HAN Info Service Does not require immediate action; provides general public health information

##This message was distributed to state and local health officers, public information officers, epidemiologists, HAN coordinators, and clinician organizations##